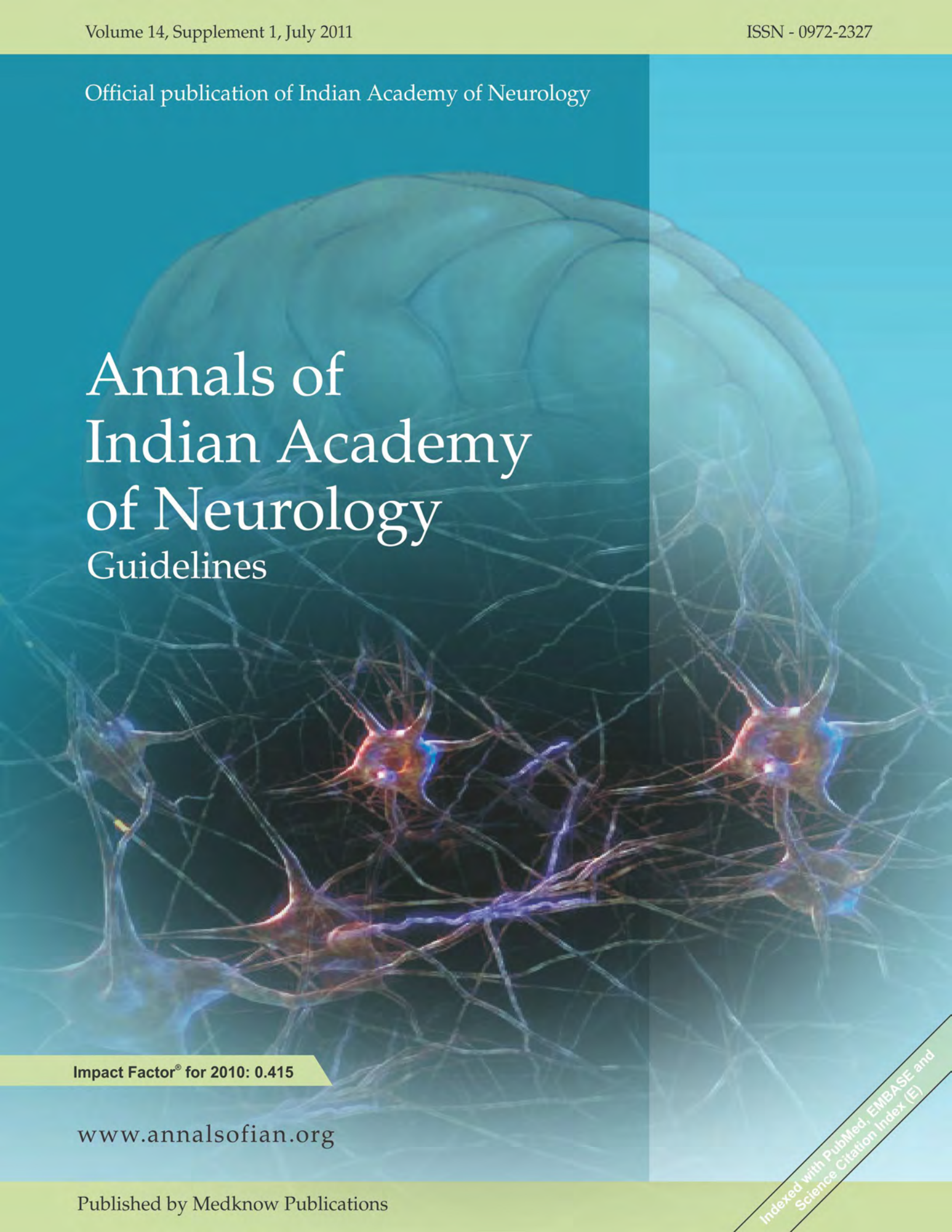


Official publication of Indian Academy of Neurology

Annals of Indian Academy of Neurology Guidelines



Impact Factor® for 2010: 0.415

www.annalsofian.org

Published by Medknow Publications

Indexed with PubMed, EMBASE and
Science Citation Index (E)

Guidelines on the diagnosis and the current management of headache and related disorders

K. Ravishankar, Ambar Chakravarty¹, Debashish Chowdhury², Rakesh Shukla³, Sumit Singh⁴

The Headache and Migraine Clinic, Jaslok and Lilavati Hospitals, Mumbai, ¹Department of Neurology, Vivekananda Institute of Medical Science, Kolkata, ²Department of Neurology, G.B.Pant Hospital, New Delhi, ³Department of Neurology, CSM Medical University, Lucknow, ⁴Department of Neurology, Medanta – The Medicity Gurgaon, Haryana, India.

For correspondence:

Dr. K. Ravishankar, A/64, Kalpataru Residency, Sion East, Mumbai – 400 022, Mumbai, India.

E-mail: dr.k.ravishankar@gmail.com

Annals of Indian Academy of Neurology 2011;14:40-59

There are at present no existing guidelines on “headache” that pertain to the Indian setting. With a view to standardizing headache diagnosis across the country and keeping in mind treatment issues peculiar to our setting, these Guidelines have been evolved to help primary care physician’s deal with headache patients. These Guidelines have been drawn up by neurologists with a special interest in headache. With limited evidence in literature regarding headache practice and treatment in India, these guidelines are more experience based than evidence based.

All contributors have adhered to the second edition of the International Classification of Headache Disorders (ICHD2-2004). In ICHD2, the first four categories deal with the primary headaches.^[1-5] The next eight categories deal with headaches due to identifiable secondary causes.^[6-13] The last two categories deal with cranial neuralgias and other causes of facial pain.^[14-17]

It is well accepted that no practice guidelines can cover all situations. Some headaches need to be handled by a neurologist but for the most part, primary care physicians are the ones who should be ideally handling headaches and these guidelines are targeted toward that end. These guidelines reflect current clinical practice trends in India. Every chapter has a brief introduction, followed by the salient diagnostic features, the way to investigate and treatment options. A summary of important practice points regarding when to refer

to a specialist has also been included. Common entities have been described in greater detail while rare conditions that are seen less often are only mentioned in passing.

The following is a brief listing of the headache conditions that are included in the second edition of The Classification of Headache Disorders of the International Headache society- ICHD2 (2004). The rubrics employed in all the chapters will be the same that is used in ICHD2.

Quick Reference to the ICHDs

2nd edition-(2004)

- a. Primary headache disorders
 - Migraine
 - Tension-type headache
 - Cluster headache and other trigeminal autonomic cephalalgias
 - Other primary headaches
- b. Secondary headache disorders
 - Headache attributed to head and/or neck trauma
 - Headache attributed to cranial or cervical vascular disorder
 - Headache attributed to non-vascular intracranial disorder
 - Headache attributed to a substance or its withdrawal
 - Headache attributed to infection
 - Headache attributed to disorder of homeoeostasis
 - Headache or facial pain attributed to disorder of cranium, neck, eyes, ears, nose, sinuses, teeth, mouth, or other facial or cranial structures
 - Headache attributed to psychiatric disorder
- c. Cranial Neuralgias and facial pains
 - Cranial neuralgias and central causes of facial pain
 - Other headache, cranial neuralgia central, or primary facial pain

Before going into the actual details, it is important to

Access this article online	
Quick Response Code:	Website: www.annalsofian.org
	DOI: 10.4103/0972-2327.83100

emphasize that the primary physicians should know when to get a neuroimaging in a headache patient to rule out the secondary causes of headache. Also, they should know when to refer the patient to a specialist or higher centre. These have been tabulated in Tables 1 and 2.

Primary Headache Disorders

Migraine

Diagnosis

Migraine is divided into two broad categories, namely migraine without aura and migraine with aura. The spectrum of migraine has now expanded [Table 3]. Most patients suffer from attacks of migraine without aura. The ICHD2 diagnostic criteria for migraine without and with aura are included in Tables 4 and 5. Migraine with aura includes a transient neurological dysfunction that may be visual, sensory or may involve speech and language. Migraine attacks in children are of shorter duration (usually 1–2 h only); the accompanying symptoms are different and may include syndromes such as abdominal migraine or periodic syndromes like cyclic vomiting.

Investigations

Neuroimaging in migraine patients is advocated only when patients present with an unexpected abnormal finding on neurologic examination, when patients present with atypical features, when attacks with migrainous features occur for the first time after the age of 40 years, or when the frequency or

Table 1: When do we ask for a CTscan/ MR scan in a headache patient?

Neuroimaging should be considered in patients with headache and an unexplained abnormal finding on the neurologic examination.
In any headache that is worsened by Valsalva maneuver
With new headaches or progressively worsening headaches
In patients with atypical headache patterns
When it is the "first and worst" headache
Headache that is persistently on the same side
Headache that is not responding to treatment
New onset headache in a patient who has cancer or is human immunodeficiency virus (HIV) positive
Headache with fever, stiff neck, nausea, vomiting.
Headache associated with papilledema, cognitive impairment, personality change, or seizures.

Table 2: When does one refer or hospitalize a headache patient?

When a severe headache presents as a medical emergency associated with intractable nausea and vomiting producing dehydration or postural hypotension.
When backup medications do not work.
When dealing with migraine complications or variants (e.g. hemiplegic migraine, suspected migrainous infarction, basilar migraine with serious neurologic symptoms such as syncope, confusional migraine, etc)
When a diagnosis has not been established during a previous similar occurrence.
When there is a diagnostic suspicion of an infectious disorder involving the central nervous system (e.g. brain abscess and meningitis)

intensity of migraine attacks continue to progress.

Treatment

Management needs to be individualized. The basic principles are as follows. Establish the diagnosis correctly; educate migraine sufferers about their condition and discuss the treatment plan; establish realistic patient expectations by setting appropriate goals; choose the drug treatment based

Table 3: Sub-classification of migraine according to the ICHD2 (2004)

Migraine without aura
Migraine with aura
Typical aura with migraine headache
Typical aura with non-migraine headache
Typical aura without headache
Familial hemiplegic migraine
Sporadic hemiplegic migraine
Basilar-type migraine
Childhood periodic syndromes that are precursors of migraine
Cyclical vomiting
Abdominal migraine
Benign paroxysmal vertigo of childhood
Retinal migraine
Complications of migraine
Chronic migraine
Status migrainosus
Persistent aura without infarction
Migrainous infarction
Migraine-triggered seizure
Probable migraine
Probable migraine without aura
Probable migraine with aura
Probable chronic migraine

Table 4: Diagnostic criteria of migraine without aura-- ICHD2

At least five attacks fulfilling criteria B–D
Headache lasting 4–72 h (untreated or unsuccessfully treated)
Headache has at least two of the following characteristics:
Unilateral location
Pulsating quality
Moderate or severe pain intensity
Aggravation by or causing avoidance of routine physical activity (e.g. walking or climbing stairs)
During headache at least one of the following:
Nausea and/or vomiting
Photophobia and phonophobia
Not attributed to another disorder

Table 5: Diagnostic criteria for migraine with aura-- ICHD₂

A There have been at least two attacks fulfilling criterion B listed below
B At least three of the following characteristics are present:
There are one or more fully reversible aura symptoms indicating focal cerebral cortical or brain stem dysfunction
Either at least one aura symptom develops gradually over more than 4 min, or two or more symptoms occur in succession
No aura symptom lasts more than 60 min; if more than one aura symptom is present, accepted duration is proportionally increased
Headache follows aura with a free interval of less than 60 min (it may also begin before or simultaneously with the aura)
No evidence of organic disease history, physical examination, and diagnostic tests exclude a secondary cause

on the frequency and severity of attacks and the presence of associated symptoms such as nausea and vomiting; consider comorbid and coexisting conditions when choosing drugs for prophylaxis; encourage patients to identify and avoid triggers.

Migraine-abortive treatment

The basic principles of abortive treatment of migraine are as follows. Tailor the treatment choice to suit individual needs (e.g. based on their severity of illness, co-morbidity / co-existing conditions and prior response to medications); use migraine-specific agents (ergotamine, dihydroergotamine (DHE), triptans) in patients with more severe migraine and in those whose headaches respond poorly to non-steroidal anti-inflammatory drugs (NSAIDs) or combination analgesics such as aspirin plus acetaminophen or caffeine; select a non-oral route of administration for migraines associated with nausea or vomiting; guard against medication overuse headache (MOH) (rebound headache). Frequent use of acute medications like ergotamine, opiates, triptans, simple analgesics, and combination analgesics containing caffeine/codeine are thought to cause rebound headache; preventive therapy given simultaneously will help reduce the need for repeated acute medications.

Nonspecific medications for acute treatment

Antiemetics

Oral antiemetics such as metoclopramide and domperidone are an adjunct to treat nausea associated with migraine.

NSAIDs, nonopiate analgesics, and combination analgesics
NSAIDs (oral) and combination analgesics containing caffeine are a reasonable first-line treatment choice for mild to moderate migraine attacks or severe attacks that have been responsive in the past to similar NSAIDs or nonopiate analgesics. Overuse of combination medications is considered to be one of the most prominent causes of rebound headache. Fortunately, analgesics containing butalbital and opioids are not easily available in our country and so their overuse is limited.

Opiate analgesics

Parenteral opiates should only rarely be used as rescue therapy for acute migraine. The risk of sedation and habituation will have to be addressed.

Specific medications for acute treatment

Ergot alkaloids and derivatives

Ergotamine oral 1 mg (available in combination with caffeine) may be considered in the treatment of patients with moderate to severe migraine. Rectal suppositories are not available in India. Safe usage limits the consumption to between 6 to 10 mg per week but ergotamine should not be used on a long-term basis. DHE, a nonselective 5-HT₁ receptor agonist, is effective in relieving headache when used intramuscularly or intravenously. Unfortunately, DHE is not available in India.

Triptans (5 HT_{1B/1D} receptor agonists): As of 2011, sumatriptan, rizatriptan, naratriptan, and zolmitriptan are the only four triptans available in India. Initial treatment with any triptan is a reasonable choice when the headache is moderate to severe. The recommended starting dose for sumatriptan is 25 mg orally. If needed one may increase the dose in increments of 50 mg to a

maximum of 100 mg per dose to a maximum of 300 mg per day. Patients with nausea and vomiting may be given subcutaneous (SC) sumatriptan. A SC injection of 1/2 cc = 6 mg may be used for severe attacks with vomiting. Both sumatriptan injection and intranasal sumatriptan are available in India. Sumatriptan should not be taken within 24 h of the administration of DHE or ergotamine. Caution must be exercised when using sumatriptan in patients with cardiac risk factors, cardiac disease, or uncontrolled hypertension. Rizatriptan is given orally in a dose of 5 or 10 mg to treat attacks of moderate severe migraine. A lower dose is recommended for patients who are on betablockers. Naratriptan is long acting and is used in a dose of 1 mg or 2.5 mg. Recurrence is less with naratriptan.

Other medications

Corticosteroids (dexamethasone or hydrocortisone) are options for rescue therapy in patients with status migrainosus.

Migraine-preventive treatment

The basic principles of abortive treatment of migraine are as follows. Preventive therapy should be employed in those patients in whom migraine has a high frequency, severity, substantial impact, and in those who have not responded to acute care. Use the least amount of the medication with the fewest side effects to gain control of the symptoms until preventive treatment can be reduced or stopped. Initiate therapy with medications that have the highest level of efficacy. Increase the dose slowly until clinical benefits are achieved without adverse events. Give each drug an adequate trial of at least 2 to 3 months. Use a long acting formulation, it will help improve compliance. Monitor the patient's headache frequency using a headache diary. Select a drug that will treat the coexistent condition and migraine. When using prophylactics, direct special attention to women who are pregnant or desire to conceive. Preventive medications may have teratogenic effects.

Beta-blockers

Not all beta-blockers are effective in migraine. Those that are efficacious include propranolol, atenolol, and metoprolol. Beta-blockers are contraindicated in patients with asthma, chronic obstructive pulmonary disease, insulin-dependent diabetes mellitus, heart block or failure, or peripheral vascular disease. When prescribing beta-blockers, start with a low dose and titrate upward as required. Once the attacks are controlled, the medication should be tapered. Propranolol can be started in a dose of 10 mg twice daily and gradually increased to a maximum of 80-120 mg per day. Doses in Indian patients are much less than in the western population.

Calcium-channel blockers

Of the available agents in this group, flunarizine is most commonly used for migraine prophylaxis. Flunarizine is useful as a first line prophylactic and can be started in a smaller dose of 5 mg at night and gradually increased to 10 mg daily. This will help avoid sedation. Flunarizine is to be avoided in patients with depression. Calcium-channel blockers are contraindicated in patients with hypotension, congestive heart failure, or arrhythmia.

Tricyclic antidepressants

Amitriptyline is useful in migraine, especially in patients

with associated TTH. 10 mg orally each night should be given at first, followed by an increase of 10 mg every week, up to 25-50 mg/day; a higher dosage may be required in the presence of comorbid depression. Contraindications include cardiac, kidney, liver, prostate and thyroid disease, glaucoma, hypotension, seizure disorder, and use of monoamine oxidase inhibitors. Tricyclic drugs should be used with caution in elderly patients because of anticholinergic side effects.

Anti-epileptic drugs

Sodium valproate, valproic acid, divalproex sodium, and topiramate have been found to be effective for migraine prophylaxis. Side effects of divalproex include nausea, alopecia, tremor, and weight gain, and their use has been associated with hepatotoxicity, particularly in children. They may also cause neural tube defects and should not be given to women who are pregnant or considering pregnancy or young women with polycystic ovarian disease (PCOD). Divalproex is started in a small dose of 250-500 mg per day and the dose is gradually increased up to 1500 mg per day with continuous monitoring for side-effects. Topiramate should be started in a small dose of 25 mg per day in adults and the dose should be gradually increased in 25 mg weekly increments to a maximum of 100 mg twice daily. Doses of topiramate for migraine in Indian patients are less than that in westerners. Topiramate should not be used in the presence of glaucoma, renal stones and tingling and numbness, diarrhea, and confusional state are some of the temporary side effects. Topiramate has the advantage of weight loss and can be used in preference to divalproex when treating obese patients.

Non-Pharmacologic Therapy

Nonpharmacologic treatment may be combined with preventive therapy to achieve additional clinical improvement for migraine relief. Behavioral treatments are classified into three broad categories: relaxation training, biofeedback therapy, and cognitive-behavioral training (stress-management training). Physical treatment includes acupuncture, cervical manipulation, and mobilization therapy.

Specific situations that warrant different treatment strategies

Migraine in children and adolescents

The only analgesics with evidence of efficacy for the acute migraine treatment in childhood and adolescents are ibuprofen 10 mg/kg body weight and paracetamol 15 mg/kg body weight. Domperidone is the antiemetic of choice in children. Ergot alkaloids should not be used in children and adolescents.

Menstrual migraine

Different drug regimes have been studied to treat this menstrual migraine. Naproxen sodium (250 mg twice daily) has been shown to reduce pain including headache in menstrual migraine. In patients who have clearly predictable menstrual cycles, one can plan a short 8-day course of peri-menstrual prophylaxis starting 5 days prior to and for 3 days during periods.

Migraine in pregnancy

Most migraine drugs are contraindicated in pregnancy.

Fortunately, most pregnant migraineurs experience less or even no migraine attacks. When migraine attacks occurs during pregnancy, only paracetamol should be administered. NSAIDs can be given in the second trimester. Triptans and ergot alkaloids are contraindicated. Propranolol and amitriptyline are the prophylactics that can be used if necessary

When to refer to a specialist?

The patient should be referred to a specialist when migraine transforms to a chronic daily headache or becomes refractory, when migraine is comorbid with severe depression or other psychiatric comorbidity, when there is associated medication overuse, and parenteral treatment becomes necessary.

Tension type headache

Diagnosis

TTH are recurrent episodes of headache lasting minutes to weeks. The pain is typically pressing or tightening in quality, of mild to moderate intensity, and bilateral in location, and does not worsen with the routine physical activity. Nausea and vomiting is usually absent, but photophobia or phonophobia may be present.

The diagnosis of TTH is essentially clinical and relies only on symptoms and signs [Table 6].

TTH has been divided into two forms, *episodic* (ETTH) and *chronic* (CTTH) in ICHD 2. Episodic tension type headache has been divided into two groups, namely *infrequent* and *frequent*. TTH is the least distinct of all headache types. Diagnosis is based chiefly on negative features (i.e. the absence of symptoms that characterize other primary or secondary headaches). However, many of the secondary headaches such as MOH chronic posttraumatic headaches, sinus/ eye disease related headaches, temporo-mandibular joint disorder related headaches, brain tumor related headaches, psychiatric disorder-related headaches, and cervical spondylosis may mimic TTH at some stage of their clinical evolution. Therefore, atypical history or abnormal clinical examination in patients of suspected TTH indicates the need for further investigation.

Treatment

Acute abortive treatment

- Simple analgesics and NSAIDs are the mainstays in the acute therapy.

Table 6: Tension type Headache---core features

Duration	30 min to 7 days
Two out of four following headache features	Bilateral location Pressing/tightening quality (non-pulsating) Mild to moderate intensity Not aggravated by routine physical activity
Associated symptoms	No nausea and vomiting (anorexia may occur) No more than one of photophobia or phonophobia
Not attributed to by another disorder	Other disorders to be excluded by clinical history and examination or by suitable investigation if necessary

- Care should be taken to avoid overuse.
- Opiates should be avoided.
- Nonpharmacologic treatment in the form of relaxation training can be of benefit in recurrent ETTH

Preventive treatment

- Tricyclic antidepressants: Amitriptyline has been found to be most effective for the treatment of CTTH. Amitriptyline should be started on low dose (10 mg to 25 mg per day) and titrated by 10-25 mg weekly till the therapeutic effect or the side effects appear. The common side effects of the drug are dry mouth and drowsiness. Serious side effects like cardiac arrhythmias, precipitation of glaucoma, and urinary retention can occur in predisposed, especially elderly subjects.
- Mirtazepine: can be given in situations where amitriptyline is either ineffective or contraindicated. Other antidepressants like SSRI and tetracyclics have been found to be not so useful.
- Recently, Botulinum Toxin Type A injection has been tried in CTTH with variable results. Currently, this is reserved for refractory patients.
- Relaxation training and biofeedback training are also helpful.
- Usually, preventives are continued for 6 months following which withdrawal is attempted. Upon withdrawal, some patients continue to remain headache free while others start to have headaches again. These patients usually require long-term treatment.

Patient education

Many patients of frequent ETTH and CTTH have grave concerns about possibility of a serious disease such a brain tumor. Correct explanations can allay these concerns. Physicians should refrain from using such terms like "psychosomatic" or "depression" which might be perceived negatively by the patient.

Headache diary

This often is very helpful for the physicians. They can measure the progression of the frequency and severity.

When to refer to a specialist?

The patient should be referred to a specialist when the diagnosis is uncertain (Multiple headache diagnoses possible), when there is a recent change in character and response pattern in a diagnosed patient, with refractory headaches that are unresponsive to first and second line drugs, with medication overuse problems including opioid dependence, with depression and anxiety not responding to standard drugs, when non-pharmacological treatment like relaxation training, and biofeedback training are required.

Cluster Headache and Trigeminal Autonomic Cephalgias

Trigeminal autonomic cephalgias (TACs) are uncommon, most often primary headache disorders which are usually short lasting and associated with cranial autonomic features. The general diagnostic characteristics of this group are unilateral head pain predominantly affecting the first division of trigeminal nerve, namely the eye, periorbital region, and forehead associated with

cranial autonomic symptoms with increased parasympathetic and decreased sympathetic activity. The TACs include the following individual headache entities: cluster headache (CH); paroxysmal hemicranias (PH); short lasting neuralgiform headache with conjunctival injection and tearing (SUNCT).

Cluster Headache

Diagnosis

An important feature of CH is the circadian periodicity with attacks occurring in a clustered form daily exactly at nearly the same time for several days and with variable periods of remission in between---hence the name CH. Severe head pain that is unilateral and orbital, supraorbital or temporal in location, lasting for 15--180 min duration if untreated. The headache may be associated with one of the following symptoms: ipsilateral conjunctival injection and/or lacrimation; ipsilateral nasal congestion/rhinorrhea; ipsilateral miosis, ptosis; ipsilateral eyelid edema; ipsilateral forehead and facial sweating; sense of restlessness, or agitation during headache. Attack frequency may range from 1 to 8 per day. CH may be classified as episodic or chronic depending on duration.

Investigation

Although most cases of CH seen in practice are primary in nature, CH may be a rare manifestation of an underlying space-occupying lesion, (especially pituitary tumors). Hence neuroimaging studies of all cases of CH are recommended.

Treatment

Abortive treatment

To terminate the acute attack.

- SC sumatriptan: Given as ½ cc = 6 mg SC injection. The injection is available in a preloaded autoinjector format which the patient himself can administer. If the injection is not available, sumatriptan can be given as a nasal spray containing 20 mg per puff.
- Oxygen: Inhalation of 100% oxygen at 6-7 L/min for 15 min is effective in 60% cases. Higher flow rate (12 L/min) may benefit some patients
- DHE: Dihydroergotamine injection or nasal spray is also effective but the drug is not available in India

Preventive treatment

To reduce the frequency and severity of the attacks.

- Verapamil: Pretreatment ECG is essential and this drug should be avoided in conjunction with beta-blockers. It is given in a starting dose of 120 mg long acting daily increased to three times daily. Constipation is the main side effect.
- Lithium: Given in a starting dose of 300 mg to be gradually increased to a max of 900 mg. Pre-check of thyroid and renal profile is necessary and lithium levels need to be monitored periodically.
- Steroids: Prednisolone in a dose of 60 mg daily to start with followed by gradual tapering. Normal precautions as while administering steroids.
- Ergotamine: Useful as adjunctive therapy. For reasons still unknown, ergotamine when used in CH on a daily basis does not usually lead to MOH.

Surgical Options

Surgery as a treatment option for CH is to be considered only in medically intractable situations when there is no improvement with verapamil, lithium, and methysergide.

Paroxysmal Hemicrania

Diagnosis

Paroxysmal hemicrania (PH) is similar to CH clinically but differs from CH in that it occurs predominantly in females, the attack duration is shorter, number of attacks is more per day, and this headache is exquisitely responsive to indomethacin. The gender bias for PH is the reverse of CH. (M: F 1:2.4). The usual onset is 20--50 years (range 6--81 years). Most cases are primary. The attacks are of 2--30 min duration. PH has been divided along the same lines as CH into two categories: episodic and chronic PH.

Investigations

Neuroimaging is seldom needed unless unusual features occur and an underlying secondary structural cause needs ruling out. Indomethacin responsiveness must be tested in all cases of suspected PH to differentiate from CH and SUNCT.

Treatment

Oral indomethacin is the drug of choice---starting at 25 mg TID and increasing to 75 mg TID if GI symptoms do not occur. Gastroprotective agents may be used concurrently. Withdrawal of indomethacin once every 6 months may be attempted.

Short Lasting Neuralgiform Attacks with Conjunctival Injection and Tearing

Diagnosis

The attacks are associated with severe to very severe pain that is strictly unilateral, neuralgic in character (short and sharp) located in the ophthalmic---trigeminal distribution attack, duration is short and in seconds (5-200), attack frequency is very high (1/day – 60/h). Autonomic features are dominant---lacrimation, conjunctival injection are usually seen. Other features may or may not be present and include rhinorrhea, nasal blockage, eye lid edema, ptosis, facial flushing, and facial sweating. There is no refractory period in between attacks. Rarely SUNCT may be caused by posterior fossa tumors and pituitary adenomas. SUNCT needs to be differentiated from trigeminal neuralgia (TN).

Treatment

- Lamotrigine (100--400 mg/day); Topiramate (50--400 mg/day); Gabapentin (600--3600 mg/day) and IV Lidocaine in intractable cases (1.3 – 3.3 mg/kg/h).
- Greater occipital nerve blockade may also help in some. Hypothalamic deep brain stimulation is now being evaluated as a preventive measure.

Other Primary Headaches

Primary stabbing headache

Diagnosis

This entity is characterized by transient and localized stabs of

pain in the head that occur in the absence of organic disease of underlying structures or of the cranial nerves. Stabs last for a few seconds and there are no accompanying symptoms, exclusively or predominantly in the distribution of the trigeminal nerve (orbit, temporal, parietal). These headaches are not accompanied by autonomic symptoms. Migraine is a common association.

Treatment

Indomethacin in a 25-50 mg per day dosage is the most effective treatment option.

Primary Cough Headache

Diagnosis

The headache is sudden, short, and bilateral and brought on by coughing or straining and generally not present at other times. Headache induced by cough or straining may be primary (or benign) and secondary. Most cases of symptomatic or secondary cough headaches are due to Arnold – Chiari Malformation Type 1 (herniation of cerebellar tonsil through the foramen magnum). Intracranial neoplasms or vascular diseases including aneurysms may also cause symptomatic cough headache.

Investigation

Primary cough headaches must occur in the absence of an intracranial pathology and hence neuroimaging (preferably MRI) must be done in all cases.

Treatment

Smoking should be stopped. Some patients respond well to indomethacin.

Primary Exertional Headache

Diagnosis

Any form of exercise precipitates the headache. The headache lasts from 5 to 48 h.

Primary Headache Associated with Sexual Activity

Diagnosis

These are headaches precipitated by sexual activity usually start as a dull bilateral ache as sexual excitement increases and suddenly become intense at orgasm. The headaches occur in the absence of any intracranial disorder. At presentation, the causal relationship to sexual activity (often suppressed by patients) must be elicited for diagnosis.

Investigation

It is known that sexual activity may cause an intracranial bleed (aneurysmal subarachnoid hemorrhage or even intracerebral hemorrhage) and hence a detailed history must be obtained.

Other conditions must be excluded by appropriate investigations (neuroimaging or CSF study), with any “thunderclap” headache where exclusion of subarachnoid hemorrhage is of paramount importance.

Treatment

Some may obtain relief with indomethacin (50 mg) prior to the sex act.

Hypnic Headache**Diagnosis**

Attacks of dull headache (sometimes severe) occur at night often awakening the patient from sleep. The headache may occur several times per month, generally lasting for 15--30 min after waking. There are no accompanying autonomic features (differentiation from CH).

Investigations

Exclusion of intracranial disorder is important and hence the need for neuroimaging.

Treatment

- A hot cup of strong coffee at bedtime helps many patients.
- Some patients benefit from may need lithium carbonate 300 mg at night or flunarizine 10 mg at bedtime.

Primary Thunderclap Headache**Diagnosis**

High intensity headache of abrupt onset mimic that of ruptured cerebral aneurysm. "True" primary thunderclap headaches are uncommon. Aneurysmal rupture must be excluded. Other conditions include bleeding from cerebral AVM, cerebral venous sinus thrombosis, and pituitary apoplexy.

Treatment

All cases of thunderclap headaches must be referred urgently to specialized units for full work-up and treatment.

Hemicrania Continua**Diagnosis**

Hemicrania continua (HC) is a strictly unilateral headache responsive to indomethacin, usually unremitting, but rare cases of remission have been reported. The diagnostic criteria for HC are as follows. Unilateral pain without side shift; pain is daily and continuous, without pain free periods; moderate severity, but with exacerbations of severe pain; autonomic features occurring during exacerbations and ipsilaterally to the pain side include conjunctival injection and/or lacrimation, nasal congestion and/or rhinorrhea and ptosis and/or miosis. Complete response to therapeutic doses to indomethacin confirms the diagnosis.

Treatment

Indomethacin in a progressively increasing dose of up to 100 mg daily orally gives complete response. Maintenance doses of indomethacin are smaller.

Secondary Headache Disorders

Eight categories deal with *headaches due to identifiable secondary causes*.^[5-12] These are detailed as follows.

Headache Attributed to Head And/Or Neck Trauma**Post-traumatic headache**

Post-traumatic headache (PTH) may be accompanied by somatic, psychologic, or cognitive disturbances. It can simulate the clinical characteristics of several primary headaches and is defined as a new onset headache resulting from injury to the brain, head, and neck.

Diagnosis

PTH can present after mild, moderate, or severe head injury. If headache, without any typical characteristics, develops within 7 days after head trauma or after regaining consciousness following head trauma and resolves within 3 months or 3 months have not yet elapsed, it is termed "acute PTH." If it persists for more than 3 months after head trauma, it is termed "chronic PTH." The distinction of 3 months between acute and chronic PTH is rather arbitrary and not based on any clear clinical or biological evidence.

Investigation

- The investigation of choice for PTH is cranial computed tomography (CT) with bone window images.
- Cranial magnetic resonance imaging (MRI) is more sensitive for detecting non-hemorrhagic focal contusions.
- With accompanying neck injury, plain x-rays cervical spine on flexion and extension are necessary to identify fracture, subluxation, or ligamentous injury of spine.

Treatment

Treatment guidelines are based on clinical experience and there are few controlled studies.

Pharmacological

- Abortive treatment for acute PTH provides short-term relief and includes NSAIDs (naproxen 500 mg bd, ibuprofen 400 mg tds). Use of these drugs should be limited to prevent rebound.
- Preventive treatment should be considered if there are more than two attacks of headache per week or headache severity or duration are high. Tricyclic antidepressants (amitriptyline 10-75 mg hs, nortriptyline 25-75 mg hs).
- The chronic, frequent use of opioids or benzodiazepines should be avoided because of the potential for habituation.
- Management of PTH should be tailored to the class of non-traumatic primary headache (chronic tension-type, migraine, etc) into which it fits.

Non-pharmacological

- Psychological evaluation is a generally accepted intervention to identify factors for delayed recovery and for cognitive assessment.
- This along with patient education, reassurance, trigger identification, biofeedback, physical therapy, joint manipulation therapy, and other occupational therapy may be considered if functional overlay is documented.

Headache Attributed to Whiplash Injury

Acute and chronic whiplash injury (WI) headaches are new

diagnostic entities in the ICHD2 classification. WI is produced when acceleration and deceleration forces act on the neck, resulting in hyperextension, hyperflexion, and occasionally hyperrotation of the cervical spine. Rear end or side-impact motor collisions are responsible for about 85% of all WI. Up to 80% of patients complain of headaches following a WI.

Diagnosis

If headache, without any typical characteristics, develops within 7 days after whiplash injury (sudden and significant acceleration/deceleration movement of the neck) and resolves within 3 months or 3 months have not yet elapsed, it is termed "acute headache attributed to whiplash injury." If it persists for more than 3 months after whiplash, it is termed "chronic headache attributed to whiplash injury."

Investigation

Plain x-rays of cervical spine on flexion and extension are necessary to identify fracture, subluxation, or ligamentous injury of spine. CT scan has improved sensitivity for detecting fracture and has been shown to be faster and cost-effective in moderate and high risk trauma patients. 3D CT images are of excellent quality. A cervical spine MRI is indicated in patients with abnormal neurological examinations suggesting the possibility of radiculopathy or myelopathy. CT scan/myelography may be more sensitive than MRI in some cases for nerve root compression. Electromyogram and nerve conduction studies may provide evidence of radiculopathy or brachial plexopathy.

Treatment

Pharmacological

- Short-term use of simple analgesics (acetaminophen 1000 mg, aspirin 500--1000 mg), muscle relaxants (tizanidine 2-8 mg tds), or NSAIDs (naproxen 500 mg bd, ibuprofen 400 mg tds) is recommended.
- Headache due to greater occipital neuralgia may respond to local anesthetic blocks with or without an injectable corticosteroid.
- Persistent headaches and neck pain may benefit from tricyclic antidepressants (amitriptyline 10--75 mg hs, nortriptyline 25--75 mg hs).

Non-pharmacological

- Short-term active exercise and physiotherapy are recommended.
- Soft collar, immobilization, and more than 3 to 5 days of rest should not be advised

Headache Attributed to Cranial or Cervical Vascular Disorders

When a new headache occurs for the first time in close temporal relation to a vascular disorder, it is coded as a secondary headache attributed to the vascular disorder. A diagnosis of headache attributed to vascular disorder usually becomes definite only when the headache resolves or greatly improves within a specified time after its onset. These include many entities of which the ones that are important to recognize are described in the following.

Headache Attributed to Subarachnoid Hemorrhage

Subarachnoid hemorrhage (SAH) is by far the most common cause of intense and incapacitating headache of abrupt onset (thunderclap) headache and remains a serious condition (50% of patients die following SAH, often before arriving at hospital and 50% of survivors are left disabled). 80% of patients with SAH have saccular aneurysms. SAH or the warning leak for saccular aneurysm or AVM should be suspected in any patient with abrupt and new onset, severe, and unremitting headache. This suspicion is heightened when headache is associated with neck rigidity, vomiting, and altered mentation.

Investigation

- CT head scan (without contrast): It is the initial investigation of choice to detect SAH with a sensitivity of >90% during first 24 h. The pattern of hemorrhage can also suggest the location of the ruptured aneurysm.
- MRI (Flair) is more sensitive than CT scan from 3 to 14 days after the hemorrhage.
- Cerebrospinal fluid examination is advised if neuroimaging is normal and the suspicion for SAH is high. RBCs are present in nearly all the cases but usually clear from 4 to 21 days. Xanthochromia is present due to the presence of oxyhemoglobin, methhemoglobin, and bilirubin. Oxyhemoglobin is released from the breakdown of RBCs after 2 to 12 h of the SAH and degrades into bilirubin by 3rd to 4th day.
- Angiography: Digital subtraction angiography (DSA), MRA, and CT angiography are required for detection and demonstration of the aneurysm. DSA is essential preoperatively to know the morphology.

Treatment

- Complete bed rest is advised, any kind of exertion should be avoided, and stool softeners should be given.
- Headache should be treated with opioids or acetaminophen and mild sedation. NSAIDs are relatively contraindicated because of the risk of gastrointestinal bleeding.
- Vasospasm is treated or prevented by the "triple H" therapy (hydration, hypertension and hemodilution) along with nimodipine.
- Surgical clipping or endovascular coiling of the aneurysm to prevent re-rupture is the definite treatment, and allows measures to prevent and treat vasospasm.
- SAH is a neurosurgical emergency. The patient should be referred as soon as possible to a specialist when the diagnosis is suspected.
- The mortality is 45% in the first month even in hospitalized patients and 50% of survivors are left with serious neurological complications.

Headache Attributed to Giant Cell Arteritis

Among the arteritides and collagen vascular diseases, giant cell arteritis (GCA) is most conspicuously associated with headache (which is due to inflammation of cranial vasculature, mostly branches of the external carotid artery). It is seen after the fifth decade. GCA has variable clinical manifestations. Recent repeated attacks of amaurosis fugax associated with headache are very suggestive of GCA. Any recent persisting headache in

a patient over 60 years of age should suggest GCA and lead to appropriate investigations. Patients may have swollen tender scalp artery. Steroids should be started promptly without waiting for the biopsy. The major risk is of blindness due to anterior ischemic optic neuropathy, which can be prevented by immediate steroid treatment.

Investigation

- The ESR and C-reactive protein are high. It is used to monitor disease activity during corticosteroid therapy.
- The diagnosis is confirmed by a biopsy of the temporal artery. Since involvement of the vessel may be segmental, positive yield is increased by obtaining a biopsy segment of 3–5 cm together with serial sectioning of biopsy specimens.

Treatment

- Treatment should be started immediately without waiting for the biopsy result.
- Typically prednisolone is started in a dose of 40–60 mg/day and continued for a month.
- Many cases of GCA are chronic and may require steroids for many years.
- The disease activity is monitored by ESR and clinical assessment.

Headache Attributed to Primary Central Nervous System Angiitis

Headache is the dominant symptom in central nervous system (CNS) angiitis (either primary or secondary). It is present in 50–80% of cases. Nevertheless, it has no specific features and is therefore of little diagnostic value until other signs are present such as focal deficits, seizures, altered cognition, or disorders of consciousness. The pathogenesis of the headache is multifactorial: inflammation, stroke (ischemic or hemorrhagic), raised intracranial pressure, and/or SAH.

Investigation

- Complete blood count: TLC is greater than 10,000/mm³ without eosinophilia in 50% of case.
- ESR is normal or mildly elevated.
- CSF often shows lymphocytic pleocytosis and elevated proteins.
- Neuroimaging shows nonspecific multifocal ischemia.
- Cerebral angiography is abnormal in 75% of cases but is not pathognomonic. It shows segmental narrowing of the medium sized vessels.
- Meningeal and brain biopsy is abnormal in only three-fourths of cases due to patchy involvement. Primary CNS angiitis is the diagnosis of exclusion which is confirmed on meningeal and the brain biopsy.
- ANA or other markers are absent.

Treatment

Patients are treated with the combination of prednisone 40–60 mg/day and cyclophosphamide 100 mg/day. The response to the treatment is far less dramatic than giant cell arteritis.

Headache Attributed to Secondary CNS Angiitis

First step is to diagnose CNS angiitis in a patient known to have

one of the many conditions that can cause angiitis. Second step is to find the underlying condition (inflammatory, infectious, malignant, toxic) in a patient presenting with CNS angiitis.

Investigation

Investigations are directed to establish systemic vasculitis. It is imperative to make the diagnosis of the CNS angiitis as well etiological diagnosis of the underlying systemic vasculitis.

Treatment

Treatment is directed toward the management of the underlying systemic vasculitis e.g. corticosteroids and immunosuppressant (azathioprine and cyclophosphamide).

Headache Attributed to Cerebral Venous Thrombosis

Headache is the most frequent and the most common presenting symptom of cerebral venous thrombosis (CVT). It has no specific characteristic. It is usually accompanied by focal neurological deficit, seizures, or signs of raised intracranial tension. Headache resolves within 1 month after appropriate treatment

Investigation

- The single best non-invasive diagnostic tool is MRI along with MRV, and in doubtful cases invasive venography should be done.
- Etiology of the CVT is established by investigations relevant to the clinical setting. In general, investigations include complete blood count, coagulation profile, anti-phospholipid antibodies, protein C, protein S, etc.

Treatment

- Intravenous heparin should be started as possible. It is safe even in the presence of hemorrhagic infarct. Weight-adjusted heparin nomograms for patients with venous thromboembolism are available.
- An initial bolus of 5000 units or 80 units/kg of unfractionated heparin followed by an infusion of 18 units/kg/h is given.
- Treatment with oral anticoagulants (warfarin/acitrom) is started along with heparin. When PT/INR value in the range of 2–3 is achieved, heparin is discontinued. Warfarin is continued indefinitely, if there is underlying coagulopathy, otherwise stopped after 3 to 6 months.
- When present, seizures are controlled with anticonvulsants.
- Intracranial hypertension is treated with mannitol, diuretics, and acetazolamide.
- Adequate hydration should be maintained
- Appropriate antibiotics are given in cases of septic thrombosis.

Cerebral Autosomal Dominant Arteriopathy with Subcortical Infarcts and Leukoencephalopathy

Cerebral Autosomal dominant arteriopathy with subcortical infarcts and leukoencephalopathy (CADASIL) is an autosomal dominant (with some sporadic cases) small artery disease of the brain characterized clinically by recurrent small deep infarcts, subcortical dementia, mood disturbances, and migraine with aura. It is due to mutations of Notch-3 gene. Attacks of migraine with aura, with or without other neurological signs are present.

It is a progressive disorder and presents with migraine with aura and stroke. As a rough guideline, migraine appears in third to fourth decade, stroke in the fourth to fifth decade and dementia in sixth to seventh decade.

Investigation

- MRI is always abnormal with striking white matter changes on T2WI.
- The diagnosis is made on a simple skin biopsy with immunostaining of Notch-3 antibodies. The disease involves the smooth muscle cells in the media of small arteries and it is due to mutations of Notch-3 gene.
- Genetic testing for Notch-3 gene mutation can also be done.

Treatment

- The treatment is largely symptomatic.
- Patients are treated as for migraine. Triptans and ergotamine should however be avoided because of their vasoconstrictive property.
- Antiplatelet agents are used for lacunar infarcts.

Headache Attributed to Non-Vascular Intracranial Disorder

Idiopathic intracranial hypertension

Idiopathic intracranial hypertension (IIH) is the persistent increase in intracranial pressure in the absence of any intracranial lesions such as intracranial tumor, hydrocephalus, intracranial infections, dural sinus thrombosis or hypertensive encephalopathy. The term benign intracranial hypertension is not used anymore because the development of the disease can entail complications like vision loss. IIH is a diagnosis of exclusion. Careful detailed history is essential. IIH most commonly occurs in young obese women. It can occur along

Table 7. Conditions associated with IIH

Obstruction to venous drainage
Cerebral venous sinus thrombosis
Jugular vein tumor
Superior vena cava syndrome
Increased right heart pressure
Endocrine disorders
Addison's disease
Hypoparathyroidism
Obesity, recent weight gain
Exogenous agents
Amiodarone
Cytarabine
Corticosteroids (particularly withdrawal)
Cyclosporine
Growth hormone
Levothyroxine (children)
Lithium carbonate
Levonorgestrel (Norplant)
Tetracycline and related compound
Minocycline
Doxycycline
Vitamin A
Vitamin supplements, liver
Infectious or post-infectious conditions
HIV infection Lyme disease
After varicella

with a primary headache disorder or in close temporal relation to a non-vascular intracranial disorder. A majority of patients have papilledema, but IIH without papilledema is also observed. Other symptoms may include tinnitus, transient visual obscurations, and diplopia.

The various conditions that can be associated with IIH are enumerated in Table 7.

Diagnosis

Progressive headache with at least one of the following characteristics and fulfilling criteria C and D: (1) Daily occurrence, (2) diffuse and/or constant (non-pulsating) pain, (3) aggravated by coughing or straining. Intracranial hypertension fulfils the following criteria. Neurological examination is normal or demonstrates any of the following abnormalities: papilloedema; enlarged blind spot; visual field defect (progressive if untreated); sixth nerve palsy. Increased CSF pressure (> 200 mm H₂O in non-obese, > 250 mm H₂O in obese) is measured by lumbar puncture in the recumbent position or by epidural or intraventricular pressure monitoring. Normal CSF chemistry (low CSF protein is acceptable) and cellularity. Headache improves after withdrawal of CSF to reduce pressure to 120--170 mm H₂O and resolves within 72 h of persistent normalization of intracranial pressure.

Investigation

- Ophthalmologic assessment is done to look for papilledema and atrophy. Visual field charting and assessment (perimetry) are performed to chart the blind spot.
- CT scan or MRI is done to show normal cranial and cerebral characteristics and exclude a venous thrombosis. A high quality ≥ 1.5 T MRI and MRV are mandatory to rule out mass lesions, dural venous sinus thrombotic occlusion, and dural and parenchymal arterio-venous, fistula or AV malformation.
- If required, a DSA may be performed to rule out a vascular malformation.
- CSF examination is done by lumbar puncture after excluding the possibility of an intracranial space occupying lesion as it is imperative to measure CSF pressure.

Treatment

- Primary goal is to prevent vision loss and symptom control. Patients without papilledema are not at risk of visual loss.
- Papilledema improves over a period of 6 months after reduction of ICP.
- No treatment is required if the patient has minimal symptoms and visual function is normal. However, all patients require serial monitoring of visual function, especially field charting for signs of visual impairment.
- Weight reduction--weight loss improves papilledema by reduction of intracranial pressure. Weight loss may also be beneficial for comorbid medical conditions like hypertension and sleep apnea.
- Reduction of CSF pressure:
 - Drugs--Medical treatment includes carbonic anhydrase inhibitors (e.g. acetazolamide and topiramate) and loop diuretics such as frusemide. The usual dose of acetazolamide is 250--500 mg tds (up to 4 g/day may be needed) alone or in combination with a loop diuretic

such as frusemide 40–120 mg/day. Corticosteroids are reserved for urgent management of patients with visual loss and should not be used for the routine treatment of IIH.

- Lumbar puncture---Repeated LPs have been used to lower ICP but have not been systematically studied. The procedure is uncomfortable, and usually not acceptable to the patient.
- Surgery---Surgery should be considered when medical treatment fails or when visual function deteriorates. The main procedures performed include lumbo-peritoneal shunt, ventriculo-peritoneal shunt, optic nerve sheath fenestration, and venous stenting.
- Tricyclic antidepressants, valproate, and calcium channel blockers should be used cautiously because of the fear of weight gain and fluid retention. Simple analgesics/NSAIDs are adequate for patients with only symptom is headache. Serial LPs may also be performed for relief of headache.

When to refer to a specialist?

A patient needs to be referred to a headache specialist or a neurologist if there is no improvement of headache after withdrawal of CSF to reduce pressure between 120 and 170 mm H₂O within 72 h, persistent headache despite adequate medications or progressive visual loss.

Spontaneous Low Pressure Headache

This condition was first recognized in 1930s. More has been learned about it since the early 1990s when MRI became widely available and after pachymeningeal gadolinium enhancement was seen in MRI of headache patients. A much broader clinical and imaging spectrum of the disease is now recognized and a substantially larger number of patients are diagnosed. Headache that occurs upon standing and is relieved by lying down occurs typically in low pressure headaches. It remains commonly misdiagnosed when there is no history of a spinal tap. Headache aggravated by valsalva maneuver is suggestive of spontaneous low pressure CSF headache. It should be considered an important and relatively frequent cause of new daily persistent headache in young and middle aged individual. However, it is important to note that not all orthostatic headaches are due to CSF leak and not all CSF leak headaches are orthostatic. Cervical or interscapular pain may precede orthostatic headache (by days or weeks). Lingering non-orthostatic headache may precede orthostatic headache (by days, weeks, or months). CSF rhinorrhea and CSF otorrhea do not cause positional headache.

Investigation

- CSF examination: opening pressure is typically low, sometimes unmeasurable. CSF protein---normal or elevated up to 100 mg/ kg and normal glucose and cells.
- CT brain scan is usually normal.
- MRI may show the following signs: diffuse pachymeningeal enhancement and descent (sagging/ sinking) of brain (cerebellar tonsils)

Treatment

- Bed rest and avoidance of upright position.
- Adequate hydration should be maintained.

- Oral or intravenous caffeine and theophylline have also been used by the virtue of their constrictive effect on intracranial arteries, leading to increased CSF pressure and reduction in headache.
- One to two cups of coffee provide good amount of caffeine.
- Epidural blood patch is given in patients who have failed initial treatment.
- Epidural infusion of dextran, fibrin glue, or intrathecal fluid infusion has also been tried.
- Surgery is considered when conservative and less invasive approaches fail.

Medication Overuse Headache

MOH is an interaction between therapeutic agents used. MOH should be suspected in a patient not responding to standard prophylactic drugs. Diagnosis is important as both acute and prophylactic drugs become ineffective as long as patient is overusing these analgesic medications. Maintenance of a headache diary is important for diagnosis, and both physicians and patients need to be educated about its use.

Diagnosis

According to the IHCD2 criteria, the diagnosis of MOH can be made in any patient who is having headache for more than 15 days per month and is regularly overusing medications for more than 3 months. Overuse is said to be present, if ergots, triptans, opioids, and combination analgesics are taken for more than 10 days per month. For simple analgesics the duration has to be more than 15 days per month. The diagnostic criteria of MOH are based on the number of tablets taken per month as well as the number of days per month for which the drug is used. They are difficult to use in our country as very few patients are in the habit of maintaining a diary.

Treatment

- Patient education and proper counseling is very important as it helps to motivate the patient for withdrawal of overused medication, to tolerate the withdrawal symptoms, and also prevent the patient from returning back to the overused drug.
- The next step is to discontinue the offending medication. It can be done either suddenly or gradually either as an outpatient or inpatient. Abrupt withdrawal is the treatment of choice. Withdrawal symptoms usually last 3–4 days. They include withdrawal headache, nausea, vomiting, arterial hypotension, tachycardia, sleep disturbances, restlessness, anxiety, and nervousness.
- Bridge therapy is required to treat withdrawal symptoms. NSAIDs, chlorpromazine, valproate, steroids, or clonidine may be used. Most experts recommend steroids for outpatient withdrawal, while IV sodium valproate can be used for in-patient withdrawal. Oral steroids 60–100 mg have been used for 5–6 days in a tapering dose. IV DHE 1–2 mg 8 hourly is preferred as it has a very low likelihood of development of medication overuse but unfortunately this drug is not available in India.
- Patient should be instructed about the proper use of acute medications. He should be advised to take it only if he has severe headache. They should be told not to take the drug in anticipation. NSAIDs such as naproxen are preferred as they rarely cause MOH.

- Migraine preventive medications are an important component of withdrawal treatment strategy and should start as soon as possible during the withdrawal process. Topiramate and divalproex sodium have been shown to be beneficial.
- Relapse following successful withdrawal is a major problem.
- Prevention of development of MOH can be done by using drugs which rarely cause MOH such as NSAIDs or have a low probability of causing MOH such as aspirin, acetaminophen, and triptans and these should be preferred for acute treatment. Use of combination analgesics, tranquilizers, and opioids should be avoided in the treatment of headache. Adequate prophylaxis can help to reduce the overuse of acute medications.

Headache Attributed to Substance Withdrawal

Headache may be produced on withdrawal of few substances after chronic use like caffeine, opioid, and estrogen. They may be diagnosed if there is temporal relationship between headache and withdrawal of substance known to produce withdrawal headache.

Headache Attributed to Withdrawal From Chronic use of Other Substances

It has been suggested but without sufficient evidence that withdrawal of the following substances may cause headache: corticosteroids, tricyclic antidepressants, selective serotonin reuptake inhibitors (SSRIs), NSAIDs.

Investigation

- No specific investigations are needed as the diagnosis is based on history of temporal relation between headache and withdrawal of offending agent.
- If there is any doubt about diagnosis then investigations are required to rule out a secondary cause.

Treatment

- Treatment is directed toward total withdrawal of the offending drug because after total withdrawal headache subsides within 1 week period.
- Acute symptomatic drugs like NSAIDs may be used if headache is problematic. Specific treatment for the opioid withdrawal should be undertaken.

Headache Attributed To Infection

Headache is a common accompaniment of intracranial infections and systemic viral infections. It is also common with sepsis and rarely may it accompany other systemic infections. In intracranial infections, headache is usually the first and the most frequently encountered symptom. The occurrence of a new type of headache which is diffuse, pulsating, and associated with a general feeling of illness and fever should raise the suspicion of an intracranial infection even in the absence of a stiff neck.

Headache Attributed to Bacterial Meningitis

Bacterial meningitis usually presents with a triad of headache, fever, and altered sensorium.

Diagnosis

Headache is the most common and may be the first symptom of bacterial meningitis. Fever and vomiting may be associated. The history is usually of short duration. There may be associated history of an ear discharge, or throat infection.

Investigation

- The hemogram shows polymorphonuclear leucocytosis and positive acute phase reactants indicative of infection
- A cerebrospinal fluid examination (CSF) is the confirmatory test.
- CSF exhibits polymorphonuclear leucocytosis with markedly decreased sugars and increased proteins.
- CSF samples should also be sent for gram stain, culture, and sensitivity to look for the causative organism.
- Chest x-ray, blood culture, and culture from throat, ear discharge, skin lesions (if any) should also be done.
- Imaging of the brain with a CT scan or MRI is not usually required for confirmation.

Treatment

- Systemic antibiotics are the mainstay of treatment and the choice of antibiotics depends upon the causative organism grown on the CSF culture/blood culture.
- In many cases, culture reports are either not contributory or are negative, in which case empirical antibiotics [Table 8] are started assuming the most common organism (depending upon the age of the patient).
- The incidence of resistance to antimicrobials is gradually increasing and therefore patients should be closely monitored, and if there is no clinical response observed in the first few days, antibiotics should be changed.

Table 8: Antimicrobials in bacterial meningitis

Age	Likely organism	Antimicrobial drug
0–12 weeks	Group B Streptococcus, Listeria	III Generation cephalosporin + Ampicillin
3 months–50 years	<i>S. pneumoniae</i> , <i>H. influenzae</i> <i>N. Meningitidis</i>	III Generation cephalosporin ± Vancomycin
50 years	<i>S. Pneumonia</i> , <i>Listeria</i> , gram-negative Bacilli	As above + Ampicillin
Skull fractures	<i>S. aureus</i> , <i>S. pneumoniae</i>	As above
Post surgery	As above	Vancomycin + Ceftazidime
Dosage of antibiotics	Ceftriaxone 4 g/day Cefotaxime 8–12 g/day Ceftazidime 8 g/day Vancomycin 3 g/day Ampicillin 12 g/day	

- Steroids are not indicated in acute bacterial meningitis except in children or in conditions where patients develop septicemic shock.

Headache Attributed to Lymphocytic Meningitis

A variety of organisms cause a lymphocytic reaction on infecting the subarachnoid space and cause lymphocytic meningitis. Headache is a common manifestation of these conditions. Causes of lymphocytic meningitis include: infections: tuberculosis, viral infections, borrelia, brucella, amoebic meningoencephalitis, toxoplasmosis, fungal meningitis; malignancy: leukemic meningitis, systemic cancer with meningeal seedlings; chemical meningitis: drug induced, contrast material induced; and systemic causes: vasculitis/connective tissue disorders

Diagnosis

Headache, photophobia, and nuchal rigidity are the main symptoms of lymphocytic or non-bacterial meningitis. Fever may or may not be an accompanying feature to begin with, but is almost invariably seen at some time during the course of the disease. Headache is usually generalized, associated with stiffness of the neck and altered sensorium in advanced cases. The onset of the symptoms may be acute as in viral infections or may be subacute or gradual as in chronic situations like fungal meningitis, tuberculosis, or toxoplasmosis. In chronic meningitis, patients usually have a history of prolonged constitutional symptoms like weight loss, malaise, and evening rise of temperature. A history of prolonged immunosuppression, steroid intake, diabetes could be contributory in some patients. Patients with viral meningitis have an acute onset of these symptoms but the clinical course of the disease is milder and recovery can be spontaneous.

Investigation

- The hemogram might be normal or may show a lymphocytic pleocytosis with a raised ESR.
- X-ray of the chest might reveal tuberculosis which might be clinically silent; it may show evidence of vasculitis or sarcoidosis.
- Unlike in acute meningitis, here imaging of the brain is usually the first investigation.
- The contrast enhanced CT scan head in patients with chronic meningitis shows evidence of basal exudates usually in the cisternal spaces, and/or evidence of vascular compromise of perforator arteries due to these exudates causing infarcts.
- CT scans also show tuberculomas, cryptococcomas, and toxoplasma granulomas which are evident as ring enhancing lesions on imaging. Evidence of hydrocephalus if present can also be seen.
- MRI of the brain is required in cases where it is difficult to differentiate between various inflammatory granulomas in the brain.
- MRI of the spine is needed if there is a suspicion of arachnoiditis.
- CSF examination is required in all cases. All patients with lymphocytic meningitis show lymphocytic pleocytosis in the CSF. Depending upon the cause the CSF sugars might be normal (chemical meningitis, lymphocytic meningitis,

toxoplasmosis, systemic vasculitis), mildly reduced (tubercular meningitis, viral meningitis) or significantly reduced (cryptococcal meningitis). Proteins in the CSF are high in almost all cases except with chemical meningitis and cryptococcal meningitis.

- The CSF should also be evaluated for cryptococci using India ink and for cryptococcal antigens (in cases of suspected fungal meningitis), acid fast bacillus (TB meningitis), PCR (TB meningitis, viral meningitis), toxoplasma antigen (toxoplasmosis). Specialized investigation are required as and when needed according to the individual case.
- HIV serology should be done in all patients with lymphocytic meningitis as it has an important bearing on the management.

Treatment

- The treatment of various forms of lymphocytic meningitis is individualized.
- There are no specific guidelines for many of these treatments and there are no studies in the Indian population to decide what regimen is ideal and correct.

Tubercular Meningitis

- Patients with tubercular meningitis (TBM) require anti-tuberculous drug treatment in the standard doses. Treatment should ideally be started as early as possible for better results.
- There are no studies to recommend which drug combination is ideal. Rifampicin (R) (15 mg/kg), isoniazid (H) (10 mg/kg), pyrazinamide (Z) (30--50 mg/kg), ethambutol (E) (15--20 mg/kg), streptomycin (1.25 mg/kg) (M) are the usually prescribed drugs. At least four drugs should be given at the start of the treatment (RHEZ/RHEM).
- It is recommended that these four drugs be given for at least 3 months and thereafter at least three drugs be continued for at least 1 year or 15 months.
- In the initial phase of treatment steroids (dexamethasone---2 mg/kg or prednisolone 1 mg/kg) are strongly recommended. Steroids need to be given for at least a month before tapering them off.
- Periodic checks of liver function tests should be carried out in all patients as the chances of developing drug induced hepatitis after starting anti-tuberculous treatment (ATT) in patients with TBM is very high.
- Patients should be reassessed periodically for improvement. If they fail to show improvement or develop persistent headache or start worsening or show focal neurological deficits, a repeat evaluation including neuroimaging should be done. Hydrocephalus needs to be managed by doing a ventriculoperitoneal shunt.
- Drug resistance is frequently observed with TBM and needs to be managed by giving second line drugs like capreomycin, kanamycin, or quinolones. If patients develop features of non-responsiveness or worsen in their clinical condition they are best referred to specialists for further management.

Fungal Meningitis

- Cryptococcal meningitis is the commonest fungal meningitis. They should be treated with antifungals. Amphotericin B, flucytosine, fluconazole are the ones that can be used.

- When diagnosed correctly, such patients are better managed at major hospitals with adequate experience in the management of fungal meningitis.

Viral Meningitis

Viral meningitis is almost always self limiting and except in some cases no specific treatment apart from general treatment is required. Some patients with extremely severe meningitis with herpes simplex virus might require acyclovir.

Headache Attributed to Encephalitis

Most common causes of encephalitis are the viral infections. Herpes simplex virus, arbovirus, and mumps are known causes of encephalitis. Except for HSV encephalitis, the causative virus is identified in fewer than half of cases of encephalitis even at referral centers.

Diagnosis

Patients with encephalitis usually present with high grade fever, headache, and altered sensorium. The headache is like any other intracranial infection and the fever is usually high grade with chills and rigors. Patients with encephalitis characteristically do not have neck rigidity. Behavioral problems are common, particularly in patients with herpes simplex encephalitis who present with apathy, aphasia, or generalized irritability. Seizures are common in viral encephalitis.

Investigation

- The CSF in encephalitis demonstrates a lymphocytic pleocytosis with normal or mildly reduced sugars and normal proteins.
- Herpes virus antigen can be detected in the CSF and PCR for viral DNA may be positive; however these tests are available only in referral centers.
- The CT scan may show changes with hypointense areas in the temporofrontal region.
- MRI is a better modality of investigation and shows areas of hypointensity in the frontotemporal region, even in cases where the CT scan may be normal.
- EEG shows abnormal lateralized discharges in the region of the frontotemporal region.

Treatment

- Acyclovir is the drug of choice and is given in 10 mg/kg every eight hourly for at least 14 days or till the CSF PCR comes negative (whichever is earlier).
- If the treatment begins in time the response to treatment can be very rewarding and a clinical cure might be expected.
- Antiepileptics might be required if there are associated seizures.

Headache Attributed to Brain Abscess

Headache is a common finding in patients with brain abscess. The presence of a febrile encephalopathy with focal neurological deficits is indicator of an evolving brain abscess. The presence of an associated ear discharge, frontal sinusitis,

head injury, or history of recent head surgery should heighten clinical suspicion. The most common organisms causing brain abscess include streptococcus, *Staphylococcus aureus*, bacteroides species, and enterobacter.

Diagnosis

- Headache is the most important feature.
- Fever may or may not be present, and if present is usually associated with chills.
- Patients may have focal deficits on neurological examination depending upon the area of the brain where the abscess is located.
- Approximately 50% will have seizures and vomiting and nausea, more so in the morning.
- Neck rigidity is usually not seen.
- Predisposing factors include infections of paranasal sinuses, ears, jaws, teeth or lungs.

Investigation

- Routine hemogram might be normal; CSF examination is contraindicated in suspected or proven brain abscess.
- Imaging of the brain clinches the diagnosis.
- In the early stage of cerebritis, the abscess appears as an area of hypodensity in the CT scan or hyperintensity on an MRI scan.
- In later stages, the abscess presents as a ring enhancing lesion with a thick ring which enhances on contrast scans.

Treatment

- Intravenous antibiotics are required in all, and surgery in most cases with brain abscess.
- A judicious combination of antibiotics, depending upon the likely organism, is to be given for a long time. Most regimens include penicillin or a third-generation cephalosporin and metronidazole. In case the abscess follows a surgery, or head injury, vancomycin should be added to the regimen.
- Antibiotics should be continued for at least 6 to 8 weeks. In non-responders, or in patients with multiloculated abscesses or in patients with large abscesses, early surgery is recommended.
- Surgery might be in the form of a thick needle aspiration or a decortication of the abscess.
- Anticonvulsants are usually given for about 3 months after surgical excision. Recurrence is common and therefore repeat imaging after 6 months after a successful treatment of the brain abscess is recommended.

Headache Attributed to Subdural Empyema

Subdural empyema is often secondary to sinusitis or otitis media. It may also be a complication of meningitis, osteomyelitis of the bones of the skull, or head injury.

Diagnosis

Patients usually present with headache which evolves acutely.

Investigation

- Early diagnosis is best made by CT or MRI which demonstrates pus accumulating in the subdural space.

Treatment

- Untreated subdural hematomas are uniformly fatal.
- Combined medical and surgical treatment is definitely required. Posterior fossa empyemas usually require a craniotomy, others might benefit with burr hole evacuation.
- Antibiotics should be given for at least 6–8 weeks.

Headache Attributed to Systemic Infection

Headache in systemic infections is usually a relatively inconspicuous symptom and diagnostically unhelpful. These conditions are mostly dominated by fever, general malaise, and systemic symptoms. Nevertheless, some systemic infections, particularly influenza, have headache as a prominent symptom along with fever and other symptoms.

Headache Attributed to HIV/AIDS

Headache in patients with HIV infection could be manifold. At the time of seroconversion, patients with HIV infection may have associated aseptic meningitis. These patients, because of diminished immunity, are prone to many cranial infections—like tubercular meningitis, cryptococcal meningitis, toxoplasmosis, etc. Effective treatment of these infections usually resolves the headache. Prophylaxis might be required in most such infections, if the CD 4 count is low in AIDS patients.

Diagnosis

Headache is dull and bilateral, reminiscent of tension-type headache. The confirmation of HIV infection is essential to discriminate headache caused by additional intracranial condition that are associated with HIV infections (e.g., cryptococcal meningitis). Therefore, it is crucial to obtain neuroimaging studies and CSF examination to distinguish between headache as a general symptom of systemic HIV infection and one that is caused by CNS infection or conditions that accompany HIV disease. Headache in AIDS can also be caused by CNS tumors like primary CNS lymphoma and metastatic systemic lymphoma.

Treatment

- The pain of HIV AIDS usually responds to routine analgesics.
- Management of other primary headaches remains the same in patients with HIV.
- Opportunistic infections in AIDS should be managed accordingly, and this results in improvement of the headache of HIV patients.

Headache Attributed to Disorder of Homeostasis

Included in this segment are headaches attributed to abnormal blood circulation in the brain. Previously these were called as *Headache associated with metabolic or systemic disease*. Headaches can be caused by sudden alteration in the arterial pressure as in pheochromocytoma, and by myocardial ischemia are included in this section. In addition, disorders of homeostatic mechanisms affecting a variety of organ systems, including altered arterial blood gases, volume disturbances as in dialysis, and disorders of endocrine function, are covered in the ICHD2.

Since there are disorders not commonly seen in practice and therefore they have not been discussed in detail.

Headache or Facial Pain Attributed to Disorder of Cranium, Neck, Eyes, Ears, Nose, Sinuses, Teeth, Mouth or Other Facial or Cranial Structures

The disorders of the structures in and around the neck and head region have long been held responsible for headache. Degenerative disorders of the cervical spine, temporomandibular joints, and diseases of the paranasal sinuses are so commonly reported to be “associated” with headaches that headache is often said to be caused by these disorders. These associations have not been supported by evidence as many people who have these disorders do not have headaches and vice versa. Therefore they are not discussed in detail here.

Headache Attributed to Disorder of Eyes

Headache attributed to acute glaucoma

Acute angle closure glaucoma presents with a painful red eye with blurring of vision and occasionally sudden blindness. A closure of this angle due to any reason tends to precipitate an attack of acute glaucoma as the intra-ocular pressure increases to very high levels in a few hours. Pain is severe, boring, and located in or around the eyes.

Diagnosis

Pain in the eye and behind or above it, fulfilling criteria C and D. Raised intraocular pressure, with at least one of the following: conjunctival injection; clouding of cornea; or visual disturbances. Pain develops simultaneously with glaucoma. Pain resolves within 72 h of effective treatment of glaucoma

Investigation

- High index of suspicion in a patient with red fiery eye
- Raised intraocular pressure in excess of 28 mmHg

Treatment

- Pilocarpine or other mitotic drugs—to make the iris cornea angle wider
- Mannitol to reduce intraocular pressure.
- Steroids.
- Surgery when condition stabilizes.

Headache Attributed to Refractive Errors

Refractive errors are very commonly thought to be associated with headache, to the extent that in every individual with any type of headache a visual acuity testing is advised. It is actually a misconception since refractive error is an uncommon cause of headache. Patients rarely complain of headache, they usually have a heaviness of the head or eye soreness on times when they are awake and watching events like television or reading.

Headache Attributed to Ocular Inflammatory disorder

Ocular inflammations are categorized in a variety of ways

including by anatomic location (cornea, iris, sclera, choroid, etc), type of inflammatory response found (e.g., nongranulomatous or granulomatous), temporal profile of symptoms (acute, subacute, chronic), and cause (e.g., viral, bacterial, fungal, autoimmune)

Diagnostic Criteria

Pain in the eye and behind or around it, fulfilling criteria C and D. Ocular inflammation diagnosed by appropriate investigation. Headache develops during inflammation. Headache resolves within 7 days after relief of the inflammatory disorder

Treatment

- Treatment of the underlying cause---antiviral, antibacterials.
- Steroids in cases of autoimmune uveitis.
- Systemic steroids in severe cases.
- Cycloplegics to abolish the associated ciliary spasm.

Referral

The patients should be referred to an ophthalmologist as soon as the diagnosis is made, as most of these conditions can be severe and require expert management.

Headache Attributed to Rhinosinusitis

Headache is commonly attributed to diseases of the nose and paranasal sinuses. As the nerve supply of the nasal sinuses is the same as that of the frontal and temporal regions, the pain of the sinuses is often referred to the skin in the region of the scalp and face. Infection/inflammation of the nose and the nasal sinuses tend to worsen the primary headaches. The diseases of the following structures can cause headache

Diseases of the Nose

- Nasal Septum-Deviation of the nasal septum may cause acute disease of the nasal sinuses that causes facial pain. Acute or chronic sinusitis can complicate the picture.
- Septal Hematoma and Septal Abscess-presents with a purulent and swollen nasal septum, pain is localized and severe, marked sensitivity to local pressure, reddening of the tip of the nose. Seen in granulomatous disease, polychondritis, or other autoimmune disorders.
- Inflammatory Rhinosinusitis-rhinorrhea, elevated temperature, pain affecting the middle part of the face and the area of distribution of the first and second trigeminal branches, and symptoms of an infection of the upper respiratory tract are the symptoms.
- **Allergic Rhinitis**---does not cause primary pain but facial pain may occur as a secondary development. It is typically seasonal presenting with nasal obstruction, nasal pain, and rhinitis.
- **Vasomotor Rhinitis**---is due to excessive reactivity of the mucous membrane. The nasal discharge is clear, and the nasal mucous membrane is swollen and displays a slight reddening compared with inflammatory rhinitis.
- **Atrophic Rhinitis**---there is reduced reactivity of the nasal mucous membrane. Mucous production is reduced, and the nasal mucous membrane is dry, encrusted, inflamed, and irritated.

Diseases of the Paranasal Sinuses

Acute Sinusitis

- Inflammation of the nasal membrane, sinuses, and their vicinity cause the symptoms of sinusitis.
- Purulent discharge and headache develop with acute nasal sinusitis, following an upper respiratory tract infection.
- Nasal polyps can also cause similar symptoms due to obstruction of the meatus of the sinuses. Maxillary sinusitis also may be caused by inflammations of dental gin, such as periapical abscesses, or of iatrogenic origin as a result of dental surgery.
- Allergies, hypothyroidism, cystic fibrosis, immune suppression, and diabetes mellitus predispose to the development of sinusitis. Trauma to the nasal sinus with fractures also may give rise to nasal sinusitis.
- Maxillary sinusitis-pain felt over the sinuses may radiate to the ear and teeth. Skin over the sinuses is tender to percussion. There is purulent discharge from the middle meatus with mild anosmia.
- Frontal sinusitis-Pain is behind the eyes and in and around the centre of the head. Maximum on getting up in the morning and improves on ambulation. There is tenderness over the sinus and the supraorbital nerve, and there is purulent discharge from the nasofrontal duct.
- Ethmoidal and sphenoidal sinusitis-the pain in both the cases is poorly localized but is usually retro-orbital and the eyes are sensitive to pressure. There is presence of post-nasal discharge.
- Chronic Sinusitis-chronic inflammation of the nasal sinus mucous membranes, which become hypertrophy and cause a permanent disturbance of nasal ciliary action and altered function of the mucous glands.

Diagnosis

- Frontal headache accompanied by pain in one or more regions of the face, ears or teeth, and fulfilling criteria C and D
- Clinical, nasal endoscopic, CT and/or MRI imaging and/or laboratory evidence of acute or acute-on-chronic rhinosinusitis;^[1,2]
- Headache and facial pain develop simultaneously with onset or acute exacerbation of rhinosinusitis
- Headache and/or facial pain resolve within 7 days after remission or successful treatment of acute or acute-on-chronic rhinosinusitis

Investigation

- Polymorphonuclear leukocytosis raised ESR.
- Culture from the pus/purulent discharge to isolate the organism responsible
- A transillumination examination can reveal pus levels in sinusitis.
- Plain radiographs of the nasal sinuses may show shadows or fluid levels. It is not possible to differentiate chronic from acute sinusitis by means of radiologic examination; this must be done on the basis of clinical features and the examination findings.
- A CT or magnetic resonance tomogram may be helpful in differentiating between a cystic and a solid lesion or a fluid level.

Treatment

- Antibiotics and oral decongestants—depending upon the organism and the sensitivity of the cultures.
- Decongestants to be given for not more than 3 days.
- Steam inhalation, warm compresses.
- Irrigation of the sinuses by saline and by antibiotics.
- Removal of the obstruction, like polyps, deposits can be cleared surgically.
- Drainage improved surgically by increasing the size of the orifices draining the sinuses.
- Correction of the deviated nasal septum.

Headache Attributed To Psychiatric Disorder

Patients with psychosis seldom complain of headache, in fact it is considered that these patients perceive lesser pain than normal individuals. Patients who have a delusion that they have a lesion in the brain like a space occupying mass, or a delusion that someone has implanted a machine inside their head which causes the headache is an example of the condition when headache can occur in patients with psychosis.

Cranial Neuralgias and Central Causes of Facial Pain

Diagnosis

Neuralgias are defined as sharp, intense, electric shock like pain abrupt in onset and termination limited to the distribution of one or more divisions of a cranial nerves or cervical roots or nerves. The facial pain syndromes have the common denominator of pain in the face which may be localized to either one or more divisions of trigeminal nerve. Unlike neuralgias, they are diffused and are more long-lasting. These diverse conditions can be divided into three broad groups as follows.

- Primary neuralgias
- Pain of cranial and cervical nerve origin other than primary neuralgias
- Central pain in the face and head
- Primary Neuralgias

Trigeminal Neuralgia

Diagnosis

Trigeminal neuralgia is a unilateral disorder characterized by electric shock like pains, abrupt in onset and termination (seconds to up to 2 min), limited to the distribution of one or more divisions of trigeminal nerve. Most commonly, the second and third divisions of trigeminal nerve get affected. In less than 5% of patients, the first division is affected. Pain is commonly evoked by trivial stimuli including washing, shaving, smoking, talking, and/or brushing the teeth which are known as trigger factors. Frequently, however, it occurs spontaneously. Trigeminal neuralgia runs a chronic course; the pains usually remit for variable periods of time to recur again. Despite severe pain, clinically no neurologic (sensory) deficit is seen in primary trigeminal neuralgias.

Etiology

Compression of the trigeminal nerve by a blood vessel at root entry zone is the cause of trigeminal neuralgia in majority of patients. In many, no cause can be found. There may be

other causes of compression of trigeminal nerve leading to symptomatic trigeminal neuralgias in 5% to 7% of patients. These groups of patients are classified as symptomatic trigeminal neuralgias. In these cases, clinically some atypical features may be found such as the presence of sensory impairment, bilaterality (like in MS), and the presence of non-paroxysmal pain.

Investigation

- All patients of trigeminal neuralgia should undergo MRI, preferably using 3D reconstruction techniques to assess the relationship of nerve with the neighborhood blood vessels and to rule out causes other than the vascular compression.

Treatment

The management of trigeminal neuralgia includes pharmacotherapy and neurosurgical intervention through various neuroablative procedures.

Pharmacotherapy

- Carbamazepine was tested by many double-blind placebo-controlled randomized trials and has been found to be efficacious in 75% of patients.
- Treatment is usually started with low dose carbamazepine (100-200 mg/day), which is then up-titrated gradually. Usually the maintenance dose of 400-1200 mg per day is required.
- Physicians have to be cautious about various side effects of carbamazepine especially in the elderly patients.
- Other second line drugs used for treating trigeminal neuralgia include oxcarbazepine, phenytoin, baclofen, lamotrigine, and gabapentin [Table 9].

Surgical Treatment

- Surgical intervention is required for patients who are refractory to medical treatment and continue to have significant pain despite adequate trial of medications. Also, specific secondary causes may be amenable to surgical treatment such as tumors.
- Following surgical options are available for refractory primary (classical) trigeminal neuralgias.
- Micro-vascular decompression (MVD) is the most definitive treatment for trigeminal neuralgia in younger patients. In MVD, the trigeminal nerve is exposed, the offending blood vessel(s) identified, and decompressed. Most common finding is a segment of superior cerebral artery compressing the nerve at the root entry zone. After decompressing it, the operator places a piece of felt between it and the nerve to ensure a permanent separation.
- Pain relief following MVD is almost always immediate and its long-term results are impressive.
- Around 80% of patients remain pain-free up to 2 years and up to 64% patients remain pain-free up to 10 years post-MVD. In expert hands, operating complications are low.
- For elderly patients or those with medical complications where MVD is not possible, percutaneous radiofrequency thermocoagulation of trigeminal nerve sensory root as it leaves the Gasserian ganglion is the procedure of choice.
- Alcohol block of the peripheral branch of the division of the trigeminal nerve that is painful can be attempted. Initial pain relief is good but the recurrence rates are high within 6 months to 1 year. The procedure can be repeated.

Table 9: Drugs for trigeminal neuralgia

Drug	Initial dose	Maintenance dose	Important and common adverse effects
Carbamazepine	100-200 mg	600-1200 mg	Sedation, dizziness, mental slowing, rash, hyponatremia, drug interactions
Oxcarbazepine	150-300 mg	600-1200 mg	Better tolerated than Carbamazepine but hyponatremia is slightly more. Spectrum of adverse effect is same
Gabapentin	100-300 mg	600-2400 mg	Sedation, memory impairment, peripheral edema
Phenytoin	100- 300 mg	300-400 mg	Sedation, ataxia, dizziness, mental slowing, rash, drug interactions, gum hypertrophy, lymphadenopathy, folate deficiency, osteopenia, acne
Lamotrigine	25-50 mg	200-400 mg	Rash, sedation, ataxia, dizziness
Baclofen	10 mg	30-80 mg	Sedation, ataxia, fatigue, GI symptoms, muscle weakness.

- Other upcoming procedures for refractory trigeminal neuralgia include percutaneous balloon compression of the trigeminal ganglion and stereotaxic radiosurgery with gamma knife. However, early recurrences are still a problem.

Glossopharyngeal Neuralgia

Diagnosis

- Glossopharyngeal neuralgia is a severe transient stabbing pain experienced in the ear, in the base of tongue, in the tonsillar fossa, or beneath the angle of jaw.
- The pain is therefore felt in the distribution of the auricular and the pharyngeal branches of the vagus and glossopharyngeal nerves.
- It is commonly provoked by swallowing, talking, coughing, and may remit and relapse similar to trigeminal neuralgia.
- Glossopharyngeal neuralgia is in many ways similar to trigeminal neuralgia.
- The diagnosis of glossopharyngeal neuralgia is essentially clinical, based on the history of characteristic paroxysms of lancinating or aching pain.
- Neurologic, dental, and imaging studies are normal.

Treatment

- Pharmacotherapy of glossopharyngeal neuralgia includes similar drugs as those used in trigeminal neuralgia. Carbamazepine, oxcarbazepine, baclofen, phenytoin, gabapentin, and lamotigine either alone or in combination have been used.

Other Cranial Neuralgias

Occipital neuralgia

Diagnosis

It refers to paroxysmal stabbing pain with or without persistent aching between the paroxysms in the distribution of greater or lesser and/or third occipital nerve, sometimes accompanied by diminished sensation or dysesthesias in the affected area. It is commonly associated with the tenderness over the nerve concerned and is blocked by local anesthetic injection of the nerve. The frequency of attacks varies from 4 to 5 per day to 2 to 7 per week. Intervening pain-free periods may last up to days weeks or months. Because of the associated feature of lacrimation and ciliary injection and periodicity, this pain syndrome can be confused with cluster like headaches. Occipital localization and neuralgic character distinguish it from cluster like headaches. In most cases, the abnormalities found to compress the C2 and its roots include single or

densely interwoven dilator veins, U-shaped arterial loops, or angiomas. Neuroimaging including x-rays, CT, meyo-CT, and MRI usually are reported to be normal. The most important diagnostic procedure is the complete relief of pain following local anesthetic blockade of the C 2 spinal nerves.

Treatment

- Pharmacotherapy is usually known to be non-rewarding in C2 neuralgia.
- Surgical approach remains the definitive treatment. Decompression of the entrapped nerves (due to scarring) can be done.

Rare cranial neuralgias

- Nervous intermedius neuralgia (brief paroxysms of pain are felt deeply in the auditory canal).
- Superior laryngeal neuralgia (pain paroxysms in throat, submandibular region and under ear and is relieved by local anesthetic block of superior laryngeal nerve).
- Nasociliary neuralgia (touching the outer aspect of one nostril causes stabbing pain lasting minutes to hours on that side of nose radiating up to the medial frontal region),
- Supra-orbital neuralgia (pain in the region of supraorbital notch and medial aspect of forehead).
- Nummular neuralgia pain in a rounded or elliptical area of about 2-6 mm diameter, most commonly in the parietal region that is now considered to be localized terminal branch neuralgia of the trigeminal nerve.

Pain of Cranial and Cervical Nerve Origin other Than Primary Neuralgia

Acute Herpes zoster

It results from reactivation of latent infection by varicella virus. Essentially it is a disease of dorsal root ganglia characterized by vesicular eruptions in the affected dermatome. About 13% of the patients have involvement of trigeminal nerve. The ophthalmic division is affected in majority (80%) of these patients.

Diagnosis

The onset of acute Herpes zoster is usually heralded by pain which precedes the vesicular eruption by a few days. The condition becomes evident once the visible eruption is seen. The initial rash of herpes zoster may mimic that of herpes simplex. The vesicles usually dry out within about 1 week and within a month they heal. The most important complication is post-herpetic neuralgia which may occur in about 10% to 15% of patients.

Treatment

- Acute herpes zoster is treated by using anti-viral agents such as acyclovir, valacyclovir, or famciclovir. Anti-viral therapy also decreases the subsequent incidence of post-herpetic neuralgia by about 80%.
- In addition to the anti-viral agents, tramadol (an opioid derivative), and tricyclic antidepressants like amitriptyline have been found to relieve the residual pain.
- Systemic steroids, particularly for ophthalmic herpes have been used. They usually do not reduce the pain but may improve the quality of life.

Post-herpetic neuralgia

Post-herpetic neuralgia is a neuralgic pain that persists in the affected the dermatome long after the vesicular eruption of acute herpes zoster has healed. The pain is typical of neuralgia. Jabs of shooting, lancinating pain on a background of constant burning, or aching pain are characteristically reported. The skin of the affected dermatome is hypoaesthetic. However, the zones of hyperesthesia from which the attacks of pain may be triggered by light touch or brushing are present around the hypoaesthetic zone.

Treatment

- Tricyclic antidepressants, pregabalin, gabapentin, opioids are effective in postherpetic neuralgia.
- Of these, amitriptyline and related tricyclic antidepressants have been most widely used and most thoroughly studied agents for the treatment of post herpetic neuralgia.
- For pain resistant to tricyclic antidepressants and gabapentin, opioids may be tried.
- Intravenous lidocaine and intravenous morphine may be used in an attempt to interrupt the persistent pain unrelieved by other medications.
- There are many surgical interventions that have been used for trigeminal post-herpetic neuralgia. These include trigeminal rhizotomy, avulsion, alcohol injection, or cryoinjection of the supraorbital nerve, alcohol injection of the trigeminal ganglia, and trigeminal tractotomy. While some of these procedures may be useful in an individual patient, none has been found to produce consistently good results for achieving prolonged pain relief.

Tolosa Hunt Syndrome and Painful Ophthalmoplegia

Diagnosis

One or more episodes of unilateral orbital pain persisting for weeks if untreated associated with paresis of one or more of the third, fourth, and/or sixth cranial nerves and/or demonstration of granuloma by MRI or biopsy suggests diagnosis of Tolosa Hunt Syndrome. Paresis usually coincides with the onset of pain or follows it within 2 weeks. Pain and paresis resolve within 72 h when treated adequately with corticosteroids. This condition is however should be considered as only one of the etiologies out of many diverse conditions which have been grouped under the broad heading of "painful ophthalmoplegia."

Investigation

- Clinical examination alone is not sufficient to find out the

causative lesion of painful ophthalmoplegia.

- As a first step, neuroimaging, preferably contrast enhanced MRI, is required to detect cavernous sinus and other pathologies.
 - This is then followed up by various tests like blood chemistry (ESR, blood sugar, connective tissue profile, serology for various infections), CSF studies, cerebral angiography and biopsy depending on suspected etiology.
2. For example, if a glaucomatous lesion is seen in cavernous sinus, further investigations for various infections by serology and CSF studies are indicated. In contrast, if a lesion suspicious of aneurysm is seen, angiography is indicated.

Ophthalmoplegic Migraine

This is now considered to be a rare disorder. Recurrent attacks of headache with migrainous characteristics associated with paresis of one or more ocular nerves (commonly the third nerve) in the absence of a demonstrable intracranial lesion on MRI define the clinical syndrome. Only finding on MRI at times may be the enhancement of third cranial nerve with gadolinium. The diagnosis is that of exclusion. All other causes of painful ophthalmoplegia need to be excluded.

Central Pain in the Face and Head

Characteristically, central pain is constant and spontaneous, although they can be evoked. Occasionally, paroxysmal pain can also occur. Central pain may have a predominantly dysesthetic character. The term thalamic pain denotes pain due to lesions or dysfunction of thalamus. Pseudothalamic *central pain* is sometimes used for central pain caused by extrathalamic lesions. Central post-stroke pain is the central pain resulting from a cerebrovascular lesion affecting the quintothalamic pathways or thalamus. Anesthesia dolorosa consists of persistent painful anesthesia in the distribution of the trigeminal nerve or one of its divisions or of occipital nerves. Despite the sensory loss, the patients feel pain which may become unbearable. Persistent idiopathic facial pain is of unknown cause occurring predominantly in middle-aged females and is a diagnosis of exclusion. The pain is usually unilateral, occasionally can be bilateral and is commonly felt around chin or nasolabial fold which may spread to wider areas of face and neck. They are usually deep, poorly localized, occur continuously throughout day and night, and worsen with time. Although many patients have overt depression, not all are depressed. Burning mouth syndrome is a condition characterized by burning sensation in the mouth without a medical or dental cause. Oral mucosa is normal on examination. Occasionally pain may be limited to tongue only (glossodynia).

Etiology of Central Pain

Vascular lesions in the brain and the spinal-cord, multiple sclerosis, spinal injuries, and neurosurgical procedures like cordotomies are common conditions causing central pain. In contrast brain tumors and traumatic brain injuries seldom cause central pain.

Diagnosis

- The diagnosis of central pain rests on the total clinical picture, in which history, symptoms, and signs indicate disease process in the CNS and the pain characteristics of which are compatible with central pain.
- The pain usually starts after the onset of the CNS disease and often the onset is delayed. Pain occurs in a regional distribution and is usually lateralized in contrast to dermatomal or nerve distribution.
- Characteristically, the pain is burning, aching, pricking, lacerating, or lancinating type. Quite often, patients report a mixture of such types of pain occurring simultaneously. Clinical examination usually reveals sensory abnormalities in the form of hypoesthesia, hyperesthesia, and dysesthesias.
- Non-sensory symptoms and signs may or may not be present. Central pain is almost always chronic usually lasting for many years.
- Anesthesia dolorosa is most commonly seen as a surgical complication of rhizotomy and thermocoagulation done to treat trigeminal neuralgia.
- Persistent idiopathic facial pain and burning mouth syndrome are diagnoses of exclusion.

Treatment

Current treatment of central pain includes pharmacotherapy and neurostimulation.

Pharmacotherapy

- The first group of drugs is those which reduce CNS hyperactivity. These include carbamazepine, lamotrigine, gabapentin, pregabalin, clonazepam, and baclofen.
- The second group of drugs increases the activity of endorphin-related pain inhibiting systems by influencing the reuptake of serotonin and noradrenalin. The classic example is antidepressant drug, amitriptyline.
- The third group includes alpha-2-agonist like clonidine and direct opiate receptor antagonists.
- Sometimes, intravenous lidocaine and intravenous morphine may be used in an attempt to interrupt the persistent pain unrelieved by other medications.

Neurostimulation

- Transcutaneous electrical stimulation has been found to be effective in central pain syndrome.
- Thalamic stimulation also appears promising.
- Excellent results have been reported following surface stimulation of the motor cortex in central post-stroke pain. All these however require expertise and are usually available in larger centers.

When to refer to a specialist?

- When the diagnosis is uncertain.
- When there is a neuralgias with atypical features
- When there is neuralgia with prominent neurological deficits.
- Refractory neuralgias and headaches unresponsive to first

and second line drugs.

- When surgical treatment is contemplated.

References

1. Headache Classification Subcommittee of the International Headache Society. The International Classification of Headache Disorders. *Cephalalgia* 2004;24:1-160.
2. Silberstein SD. Report of the Quality Standards Subcommittee of the American Academy of Neurology. Practice parameter: Evidence-based guidelines for migraine headache (an evidence-based review). *Neurology* 2000;55:754-63.
3. Pryse-Phillips WE, Dodick DW, Edmeads JG, Gawel MJ, Nelson RF, Purdy RA, *et al.* Guidelines for the diagnosis and management of migraine in clinical practice. *CMAJ* 1997;156:1273-87.
4. Lance JW, Goadsby PJ. Mechanisms and management of headaches. 7th ed. Oxford: Butterworth – Heinemann; 2005.
5. Chakravarty A, Mukherjee A, Roy D. Trigeminal autonomic cephalgias and variants: Clinical profile in Indian patients. *Cephalalgia* 2004;24:859-66.
6. Ashina S, Bendtsen L, Ashina M. Pathophysiology of tension-type headache. *Curr Pain Headache Rep* 2005;9:415-22
7. Fumal A, Schoenen J. Tension-type headache: Current research and clinical management. *Lancet Neurol* 2008;7:70-83.
8. Bendtsen L. Drug and nondrug treatment in tension-type headache. *Therap Adv Neurol Disord* 2009;2:155-61.
9. Holroyd KA, O'Donnell FJ, Stensland M, Lipchik GL, Cordingley GE, Carlson BW. Management of chronic tension-type headache with tricyclic antidepressant medication, stress management therapy, and their combination: A randomized controlled trial. *JAMA* 2001;285:2208-15.
10. Somand D, Meurer W. Central nervous system infections. *Emerg Med Clin North Am* 2009;27:89-100.
11. Tyler KL. Neurological infections: Advances in therapy, outcome, and prediction. *Lancet Neurol* 2009;8:19-21.
12. Bigal ME, Gladstone J. The metabolic headaches. *Curr Pain Headache Rep* 2008;12:292-5.
13. Smitherman TA, Baskin SM. Headache secondary to psychiatric disorders. *Curr Pain Headache Rep* 2008;12:305-10
14. Zeberholzer K, Wober C, Vigl M, Wessely P, Wöber-Bingöl C. Facial pain and the second edition of the international classification of headache disorders. *Headache* 2006;46:259-63.
15. Cranial neuralgias and central causes of facial pain. Mechanism and management of headache. In: Lance JW, Goadsby PJ, editors. Philadelphia, PA: Elsevier Butterworth Heinemann; 2005. p. 333.
16. Tasker RR, Watson CP. The treatment of central pain. Neurological therapeutics: Principles and practice. In: Noseworthy JH, editor. London, New York: Martin Dunitz; 2003. p. 214.
17. Sadosky A, McDermott AM, Brandenburg NA, Strauss M. A review of the epidemiology of painful diabetic peripheral neuropathy, postherpetic neuralgia, and less commonly studied neuropathic pain conditions. *Pain Pract* 2008;8:45.

How to cite this article: Ravishankar K, Chakravarty A, Chowdhury D, Shukla R, Singh S. Guidelines on the diagnosis and the current management of headache and related disorders. *Ann Indian Acad Neurol* 2011;14:40-59.

Received: 12-01-11

Source of Support: Nil. **Conflict of Interest:** None declared.